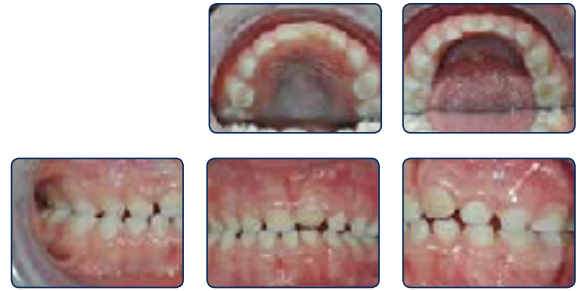
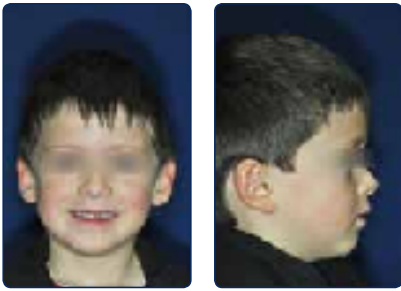

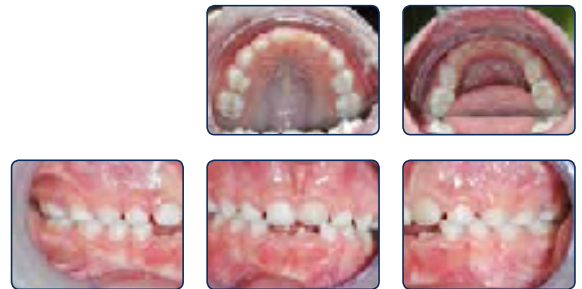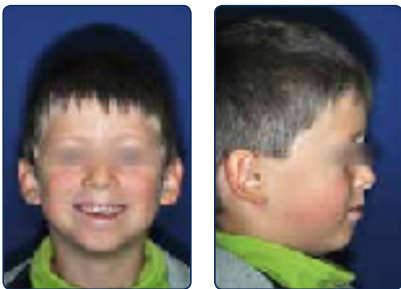Case treated by EF Kid

Yann

5
y.o.



With EF Kid

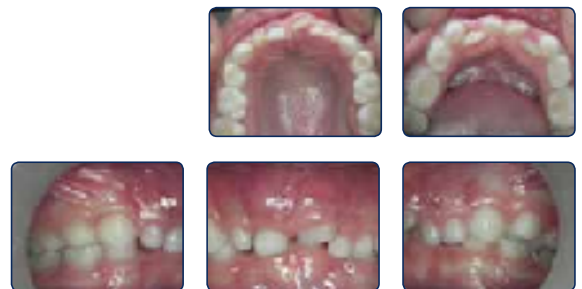
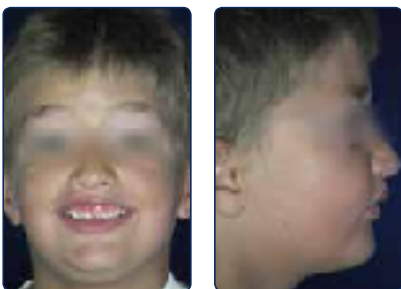

Results: • Recentered TMJs • Good chewing

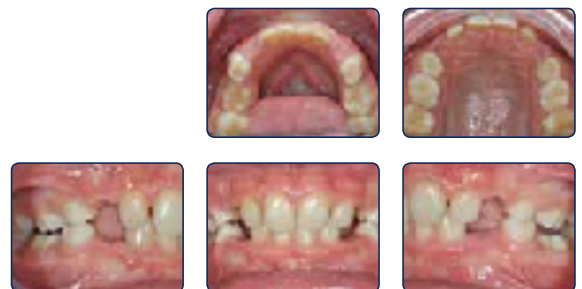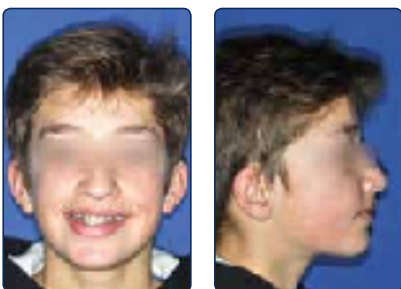Case treated by EF Start

Jules

6
y.o.



With EF Start

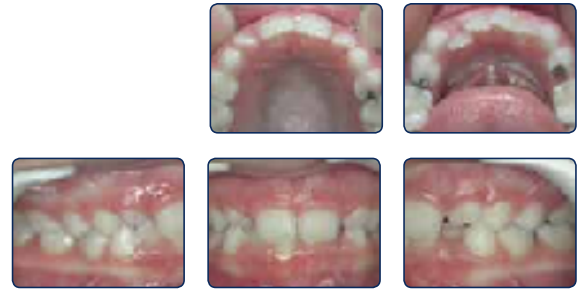
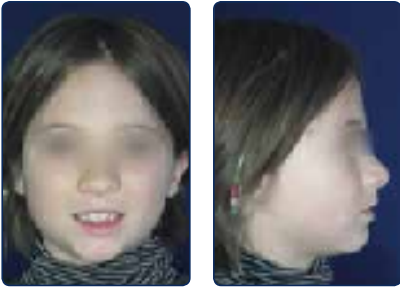
Results: • midlines correction • improved gummy smile (after EF Start then EF T Slim)

Case treated by EF Start...

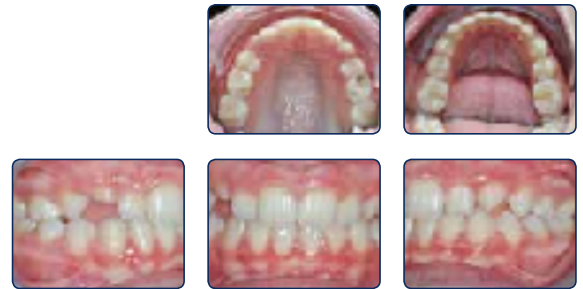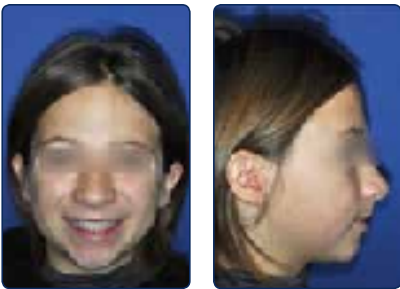Amélie

8
y.o.



... then by EF T Slim...

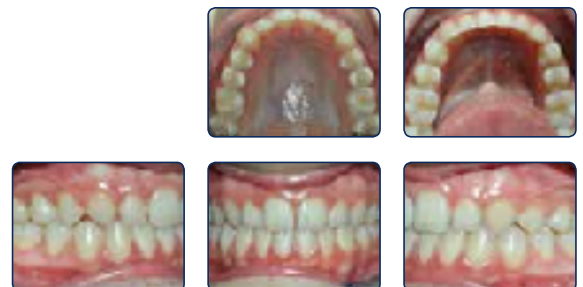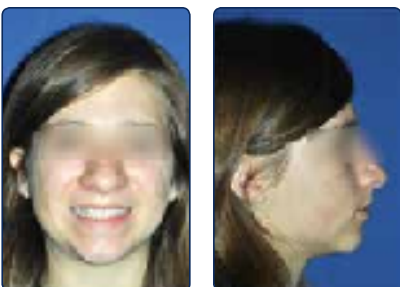With EF T Slim



Results: • overbite correction • crowding correction

... finally with EF Guide

With EF Guide

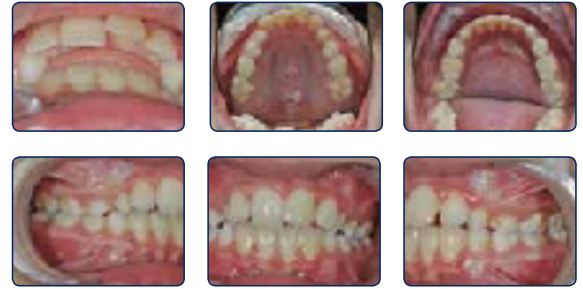
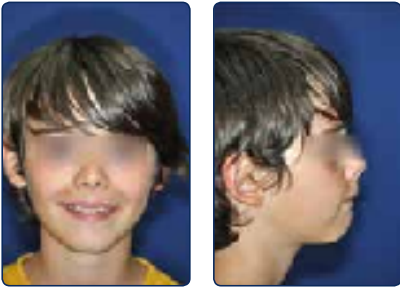
Results: • midlines correction • buccal segments guiding

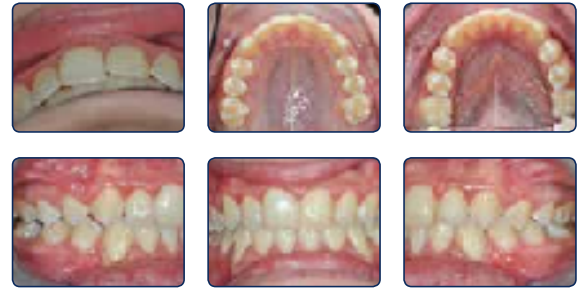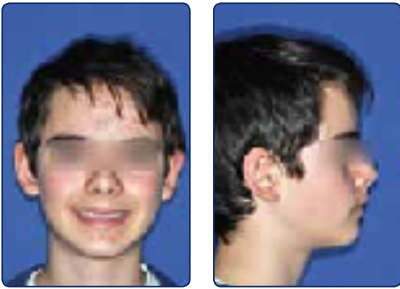Case treated by EF Classe II Slim

André

10
y.o.



With EF Class II Slim

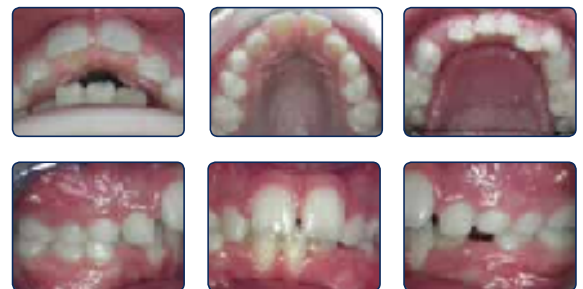
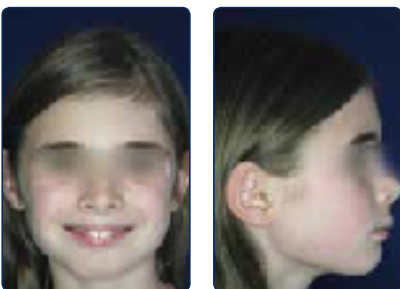
Results: • overjet and deep bite correction, management of midlines and arch recontouring

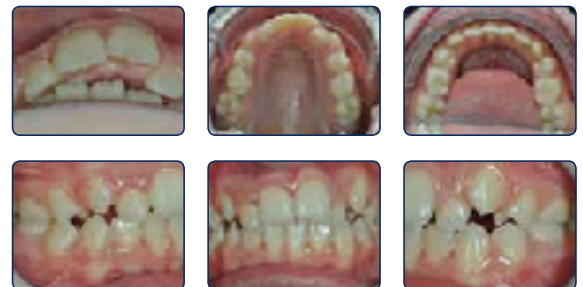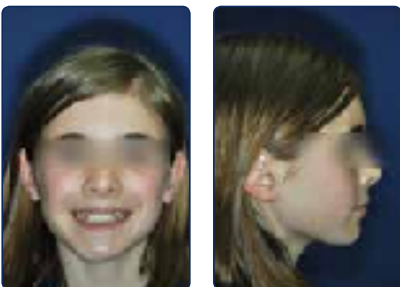Case treated by EF Classe II Standard

Maeva

11
y.o.



With EF Class II Standard

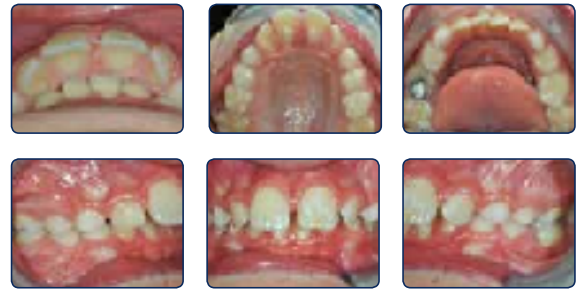
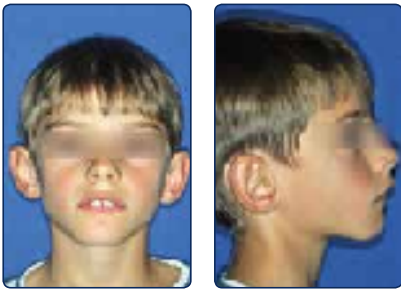
Results: • Class II correction • arch recontouring • then multibanded treatment – upper and lower

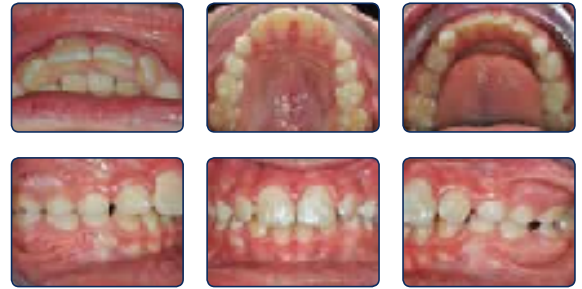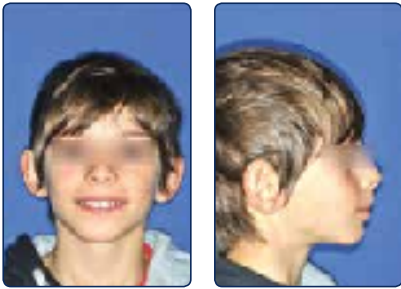Case treated by EF Classe II 2 Steps...

Evan

9
y.o.



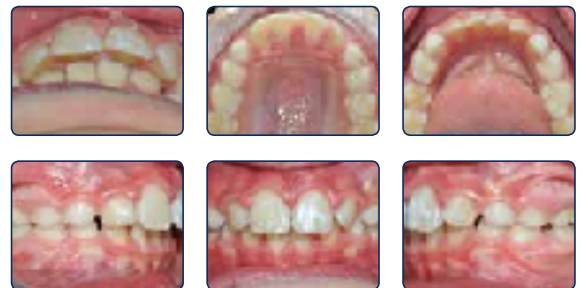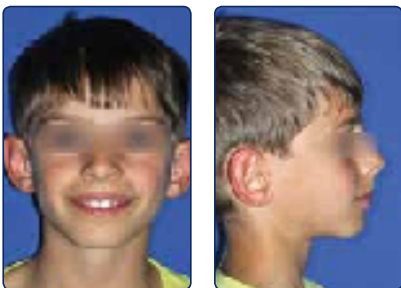EF Class II 2 Steps for 3 months



Results: • improvement of the overjet, without rabbiting

... then with EF Classe II Standard...

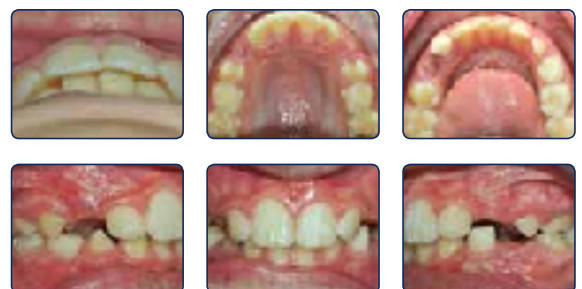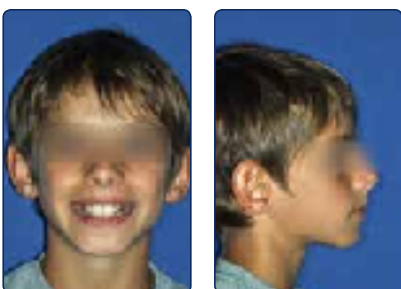
EF Classe II Standard for 3 months



Results: • improvement of the overjet, then of the deep bite

... then with EF T Slim

EF T Slim for 6 months

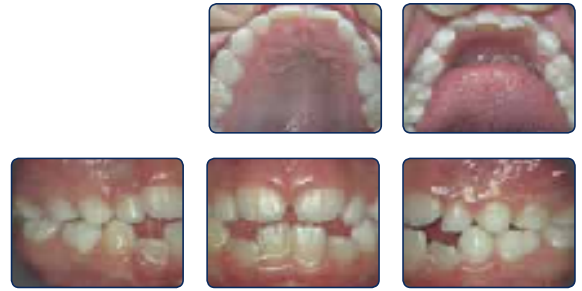
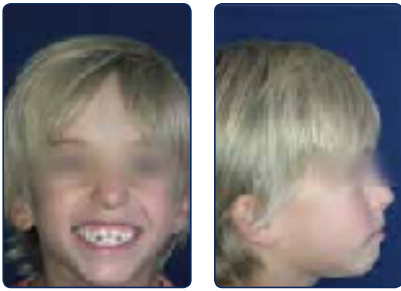
Results: • Class II corrected • waiting for buccal segments (1 year in treatment)

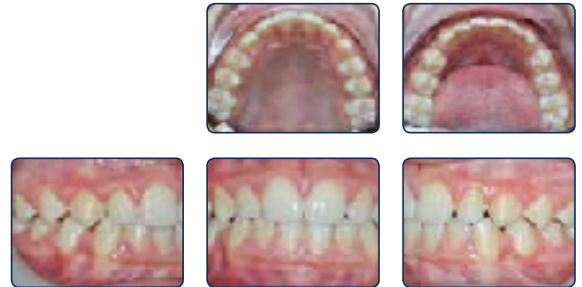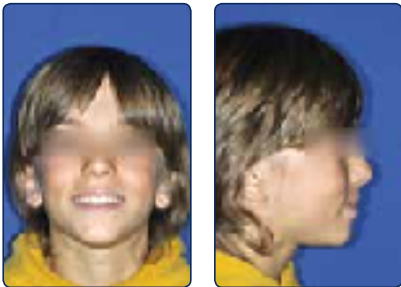Case treated by EF Classe III Petit

Gabin

7
y.o.



EF Class III Petit then EF T Slim

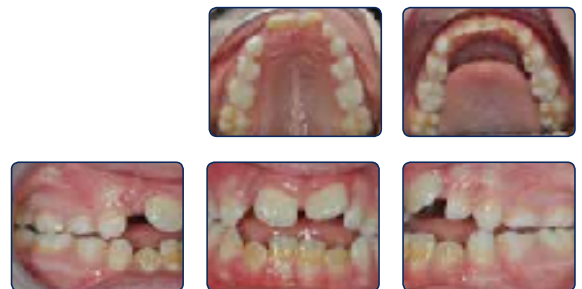
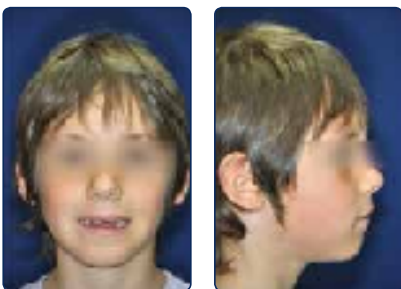
Results: • correction of the anterior crossbite and development of the premaxilla

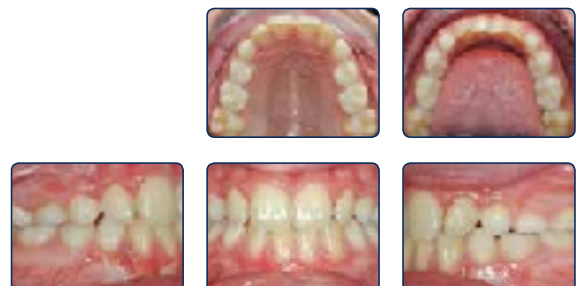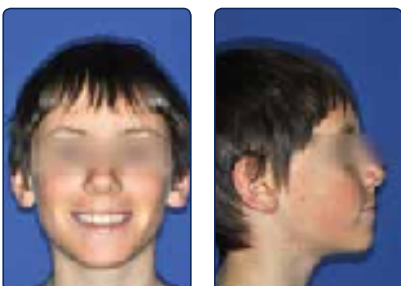
Case treated by EF Classe III Standard

Vivien

8
y.o.



With EF Class III Standard

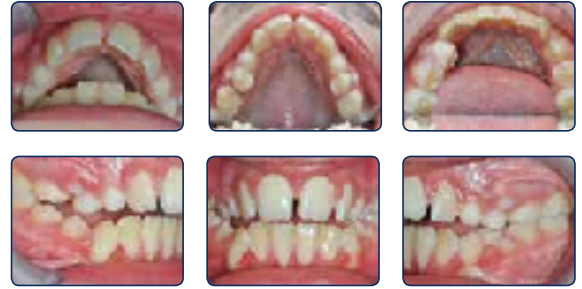
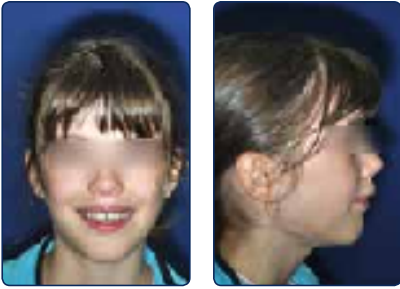
Results: • correction of Class III and open bite • arch recontouring • improvement of the ventilation

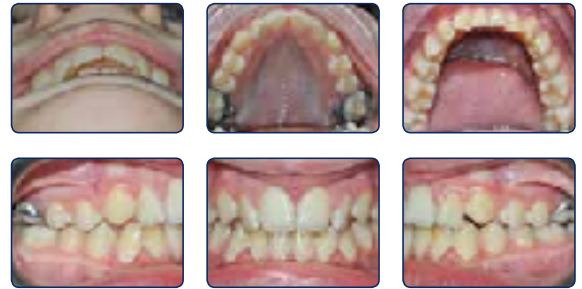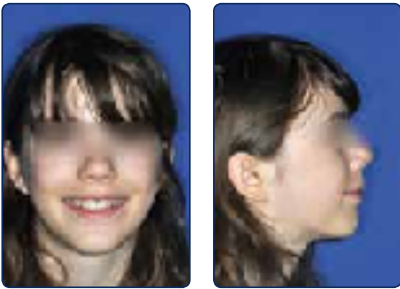Case treated by EF Braces

Blandine

12
y.o.



Quad-Helix along with EF Braces

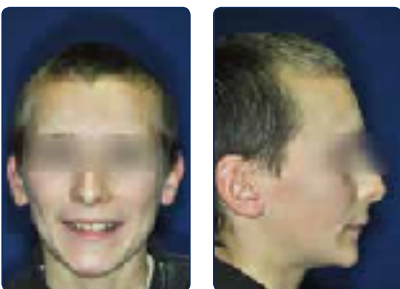


Results: • overjet correction, arch recontouring • then multibanded fixed appliance

Case treated by EF Protect

Samuel

14
y.o.

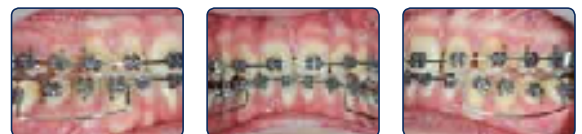


First, an EF Braces...

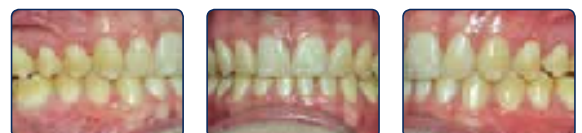... then an EF Protect with brackets on the upper...



... and then, upper and lower brackets...



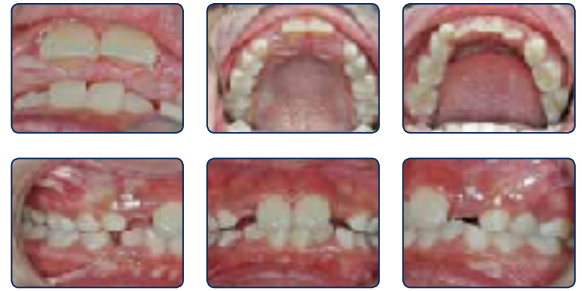
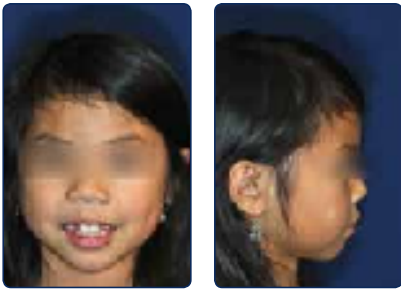... result



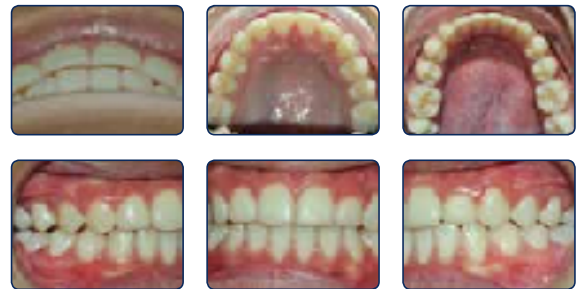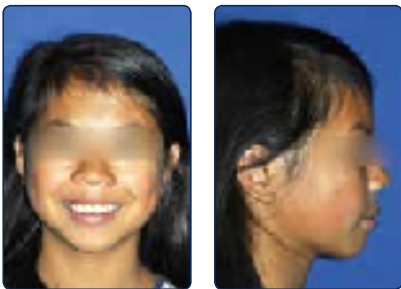Case treated by EF Profil

Manon

8
y.o.



EF Class III, then EF Profil



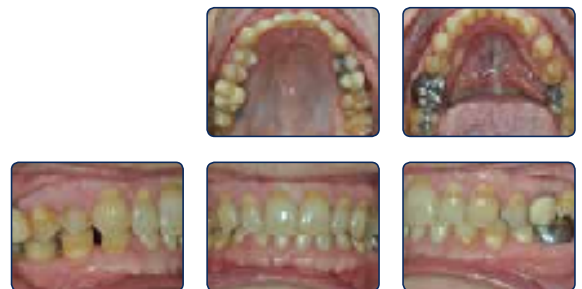- Results:
- 1st step: Class II and crowding corrected
 - 2nd step: improvement of the transverse direction with EF Profil

Case treated by EF TMJ

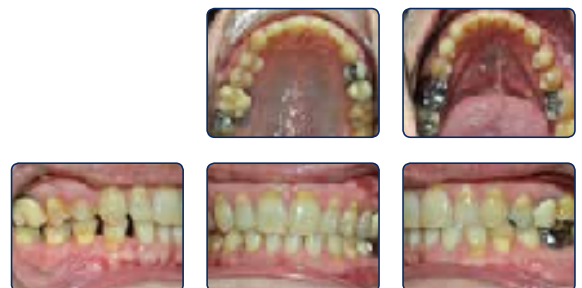Anita

47
y.o.

Bruxism and mandible lock



EF TMJ then EF guide



- Results:
- less pain
 - wider opening
 - anterior and transverse unlocking
 - possible follow-up with braces for occlusal equilibration

Case treated by Interceptor

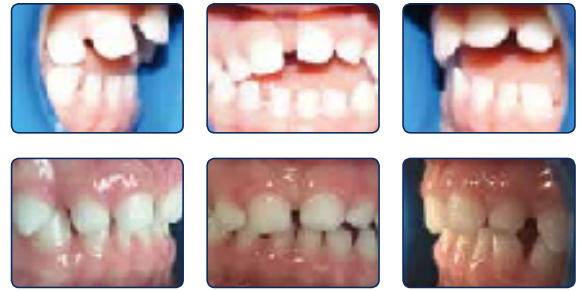Raphaël

3
y.o.

Interceptor

Results:

- closing of the open bite
- lips seal restored

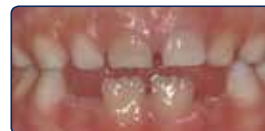

Case treated by Exerlangue

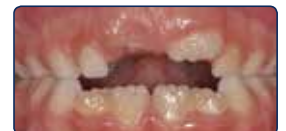Lucas, 7y.o.



Swallowing before
Exerlangue



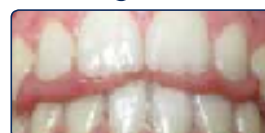After 5 weeks of
wear, 1 hour per day



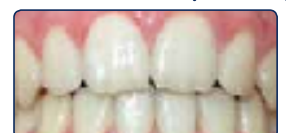Arnaud, 15 y.o.



Swallowing before
Exerlangue



After 5 weeks of
wear, 1 hour per day



Results: • Good command of swallowing • Elevated position of the tongue with tongue/palate swallowing